CHEST Postgraduate Education Corner
CONTEMPORARY REVIEWS IN CRITICAL CARE MEDICINE

Pneumothorax in the Critically Ill Patient

Lonny Yarmus, DO, FCCP; and David Feller-Kopman, MD, FCCP

Pneumothorax in critically ill patients remains a common problem in the ICU, occurring in 4% to 15% of patients. Pneumothorax should be considered a medical emergency and requires a high index of suspicion, prompt recognition, and intervention. The diagnosis of pneumothorax in the critically ill patient can be made by physical examination findings or radiographic studies including chest radiographs, ultrasonography, or CT scanning. Ultrasonography is emerging as the diagnostic procedure of choice for the diagnosis and management guidance and management of pneumothoraces, if expertise is available. Pneumothoraces in unstable, critically ill patients or in those on mechanical ventilation should be managed with tube thoracostomy. If there is suspicion for tension pneumothorax, immediate decompression and drainage should be performed. With widespread use of CT scanning, there have been more occult pneumothoraces diagnosed, and the most recent literature suggests that drainage is preferred. In patients with a persistent air leak or failure of the lung to expand, current guidelines suggest that an early thoracic surgical consultation be requested within 3 to 5 days. ***CHEST 2012; 141(4):1098–1105***

Abbreviations: PSP = primary spontaneous pneumothorax; SSP = secondary spontaneous pneumothorax

Pneumothorax is defined as air identified within the pleural space and is a commonly encountered problem in the critical care setting. The prevalence of pneumothorax in ICU patients requiring mechanical ventilation ranges from 4% to 15%,[1,2] and it remains one of the most serious complications of positive pressure ventilation. Fortunately, if identified in a timely fashion, pneumothoraces in the ICU can be treated effectively with pleural drainage, minimizing both acute and long-term adverse sequelae.[3]

The pleural space is considered a potential space defined by visceral pleural lining of the lung and parietal pleural lining of the chest wall, diaphragm, and mediastinum. Under normal conditions, the pleural space in the human is a sealed cavity that contains a small volume of fluid estimated to be 0.26 mL/kg body mass, or 15 to 20 mL.[4] It is not clear why humans have a pleural space, because other species, such as elephants, do quite well without a pleural space, as do humans following pleurodesis.[5] Postulated reasons for having a pleural space containing a small amount of liquid include allowing a reduced surface tension and friction for efficient lung expansion. The elasticity of both the chest wall and the lung parenchyma in opposing directions results in a slightly negative pressure within the pleural space at functional residual capacity. Despite the negative pleural pressure, air does not normally enter the pleural space because the intact visceral pleura and chest wall prevent air access. If air is discovered within the pleural space, there are three mechanisms by which the air may have entered:

(1) A communication between the pleura and alveolar space via visceral pleural rupture
(2) A communication between the pleural space and the atmosphere, most commonly due to penetrating chest trauma or introduction of air during pleural procedures
(3) The presence of gas-producing organisms within the pleural space[6]

The causes of pneumothoraces are clinically classified into two main categories: spontaneous (no known

Manuscript received July 5, 2011; revision accepted November 2, 2011.
Affiliations: Interventional Pulmonology, Division of Pulmonary and Critical Care Medicine, The Johns Hopkins Hospital, Baltimore, MD.
Correspondence to: Lonny Yarmus, DO, FCCP, Interventional Pulmonology, The Johns Hopkins Hospital, 1830 E Monument St, 5th Floor, Baltimore, MD 21205; e-mail: lyarmus@jhmi.edu

DOI: 10.1378/chest.11-1691

precipitating factor) and nonspontaneous. Primary spontaneous pneumothorax (PSP) occurs in patients without a known history of underlying lung disease, most commonly in male smokers with an ectomorphic body type who report the sudden onset of ipsilateral chest pain.[7] The underlying pathogenesis of PSP is unknown, but most experts believe it is due to increased pleural porosity or subpleural bleb rupture.[8,9] Secondary spontaneous pneumothorax (SSP) results from a visceral pleural leak in patients with a known underlying lung disease such as emphysema, cystic fibrosis, or lymphangioleiomyomatosis.[10] Because patients with SSP have underlying lung disease with less cardiopulmonary reserve, they typically present more acutely than those with PSP and require more urgent drainage, with hospitalization recommended.[11]

Nonspontaneous pneumothorax is due to traumatic or iatrogenic injury of the chest wall or lung. Iatrogenic pneumothorax in the ICU most often occurs after central venous access, thoracentesis, transbronchial lung biopsy, or positive pressure ventilation.[12] There are multiple risk factors for acquiring a pneumothorax in mechanically ventilated patients in the ICU. A recent study by Papazian et al[13] showed a significant reduction in pneumothoraces in patients with severe ARDS who were randomized to receive 48 h of paralysis. An earlier study in the pediatric population showed that the prevalence of pneumothorax in ventilated patients was significantly higher in the era before protective lung strategies with low tidal volumes were the standard of care.[14] Higher prevalences of pneumothoraces were seen in patients with ARDS, but not in those treated with prone positioning or different ventilatory strategies related to airway pressures alone.[15-17] Traumatic pneumothorax is also commonly seen in the ICU. It is the second-most common sign of chest trauma following rib fracture, and occurs in up to 50% of chest trauma victims (Fig 1).[18]

FIGURE 1. Anterior-posterior chest radiograph showing a right pneumothorax after right internal jugular central line placement.

Diagnosis of Pneumothorax

The diagnosis of pneumothorax in the critically ill patient can sometimes be made with information from the history and physical examination, noting acute onset of dyspnea or chest pain, tachycardia, hypotension, decreased breath sounds, pulsus paradoxus, and contralateral tracheal deviation. Although clinical features can be used to diagnose the presence of a pneumothorax, it should be noted that many of these findings are nonspecific and have not been a reliable indicator of size, especially in the case of SSP, in which the severe symptoms of dyspnea can be out of proportion to the size of the pneumothorax, and underlying emphysema can cause diminished breath sounds. An unanticipated reduction in tidal volume or increase in airway pressures resulting from a reduction in compliance may be associated with pneumothorax but can also be found in other disease states and therefore have the potential to be misinterpreted under different clinical scenarios. For instance, the increases in peak and plateau pressures from pneumothorax are due to reduced compliance, which is in contrast to other disease states in which the increase in peak pressure signifies an increase in airway resistance. As a result, radiologic data remains the gold standard for the diagnosis of pneumothorax.[19]

Thoracic Ultrasonography

Ultrasonographic assessment of pneumothorax has emerged recently as the standard of care in facilities with physicians trained in bedside ultrasonography.[20,21] The first diagnosis of a pneumothorax by ultrasonography was reported in a horse in 1986.[22] Over the past several years, the use of portable ultrasonography has greatly enhanced its diagnosis and the management of patients with pneumothorax. There are several advantages of ultrasonography over standard chest radiography and CT scanning, including the absence of radiation, portability, real-time imaging, and the ability to easily perform dynamic and repeat evaluations. As a result, when a critical care ultrasonography-trained physician is available, ultrasonography is the preferred first-line diagnostic test to exclude pneumothorax in the ICU.

Because air and bone block the transmission of ultrasonography waves, the use of ultrasonography for the evaluation of pneumothorax and parenchymal lesions has been traditionally thought to be an inferior technology. The acoustic window is limited to the intercostal space, and the parietal and visceral pleura are seen as two hyperechoic lines, typically <2 mm thick.[23] Without the presence of pleural fluid, identification

of the visceral and parietal pleura can be difficult.[24,25] The lung, filled with air, appears as patterns of bright echoes caused by reverberation artifact. During inspiration, these echoes become brighter (ie, more hyperechoic). Movement of the underlying lung with respiration produces a "sliding" or "gliding" sign, and this dynamic movement identifies the visceral pleura and lung parenchyma. Diaphragmatic movement can also be visualized in real time and is a key reference point when starting to perform ultrasonography examination of the pleural space. The liver and spleen are used as an echo reference for the definition of hypo-, iso-, and hyperechoic reflections.

B lines, also known as comet tail artifacts, are caused by echo reverberations of the air-filled lung and appear as narrow hyperechoic ray-like opacities extending from the pleural line to the edge of the ultrasonography screen that move with lung sliding without fading. Because pleural air would block the visualization of the underlying lung, the presence of B lines and lung sliding rules out a pneumothorax with a negative predictive value of 100% in the location of the chest probe.[26,27] It is important to examine several locations on the thorax, especially the superior anterior and lateral chest wall, where air would normally accumulate. Lung sliding can be limited by pleural-parenchymal adhesions, endobronchial obstruction, or diaphragmatic paralysis, and, therefore, the main use of ultrasonography for assessment of pneumothorax lies in its ability to rule out a pneumothorax. Lung ultrasonography can also be used to determine pneumothorax by identifying the point where the lung separates from the chest wall. This is seen as an area where normal lung sliding meets an area where no lung sliding is seen, and it has been termed the "lung point." The lung point can be visualized with both B-mode and M-mode ultrasonography, and, when seen, has a 100% specificity for pneumothorax.[28] The sensitivity of the lung point for pneumothorax, however, is inversely proportional to the size of the pneumothorax, because a large pneumothorax would prevent the parenchyma from opposing the chest wall (Fig 2).

A study comparing ultrasonography to CT scan and chest radiographs for the diagnosis of occult pneumothorax showed that the use of ultrasonography detected 92% of occult pneumothoraces diagnosed with CT scan.[29] ultrasonography can also be used to confirm resolution of a pneumothorax after pleural drainage, is more sensitive then chest radiography, and allows for rapid reassessment.[30] Ultrasonography has been used to rule out pneumothorax after central line placement, as well as after transbronchial biopsy.[31,32] Though there is a learning curve associated with the use of chest ultrasonography, it is relatively short.[33]

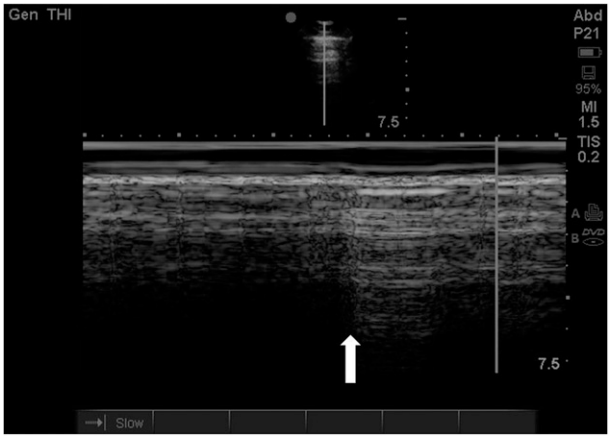

Figure 2. M-mode ultrasonography of the lung point sign, which identifies the point where the lung separates from the chest wall (arrow) at the site of the pneumothorax.

CT Scanning

CT scan is the gold standard test for both the diagnosis and sizing of pneumothorax.[34] In the era of ultrasonography, however, the cost and inconvenience of CT scanning in critically ill patients must now be considered. The technology is particularly useful in patients with significant underlying lung disease, which may obscure chest radiographic findings. Specifically, CT scanning is an excellent tool to differentiate bullous lung disease from pneumothorax, which may help avoid unnecessary drainage attempts that may result in the creation of a parenchymal-pleural fistula.[35] Pneumothorax size can best be calculated with CT imaging. However, the size of the pneumothorax is less important than the degree of clinical severity, and performing a CT scan simply to quantify the size is unnecessary because it is unlikely to alter management (Fig 3).[36,37]

Chest Radiographs

Chest radiographs have traditionally been the first test ordered for suspected pneumothorax but, as discussed earlier, in the era of bedside ultrasonography this is no longer the standard of care.[38] In the critically ill, the traditional erect posterior-anterior expiratory film is not practical and thus, the supine or semirecumbent anterior-posterior film is frequently obtained.[39] Expiratory chest radiographs were recommended previously in cases in which a small pneumothorax was suspected and not confirmed on standard views; however, these do not significantly increase the diagnostic yield and are especially challenging to obtain correctly in the ventilated patient.[40] As a result, expiratory films are not recommended in the current pneumothorax guidelines.[41]

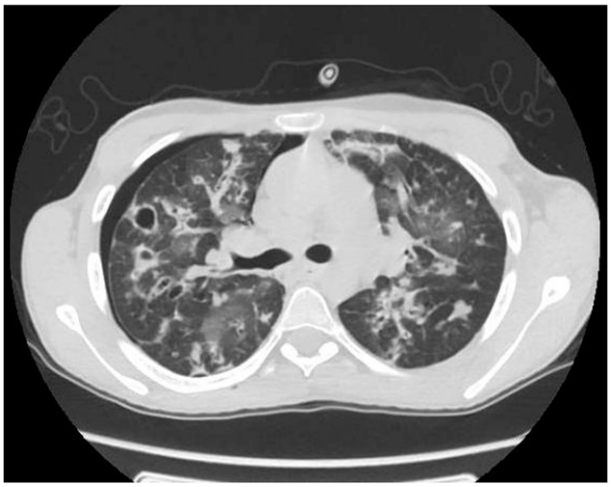

FIGURE 3. CT scan of a right pneumothorax in a patient with cystic fibrosis.

Radiographic findings of a pneumothorax in the supine patient may present in several ways. In addition to the classic findings of lung collapse in or around the apices, in the supine position air can have a propensity to collect in a subtle fashion along the anterior space without a clear lung edge finding. As additional air accumulates, it can track further around the chest and result in the classic deep sulcus sign (Fig 4).[42]

ICU clinicians are often presented with additional challenges in diagnosing pneumothoraces in patients with ARDS or acute lung injury. Given that ARDS patients often have both parenchymal and pleural abnormalities, loculated pneumothoraces may occur, and obscuration of the pleural line by overlying abnormal parenchyma may make the diagnosis more challenging. Additionally, pleural adhesions in conjunction with differences in pulmonary compliance may result in various segments of lung collapse, with overdistension in others.[43] In a retrospective cohort study of 60 patients who developed a pneumothorax during their ICU stay, 33 (55%) carried a diagnosis of ARDS.[44] Although pneumothoraces in patients with ARDS most commonly occur in anteromedial or subpulmonic anatomic locations, they can also be found in the posteromedial or apicolateral space, as well as within the pleural fissures and pulmonary ligament (Fig 5).[39,45]

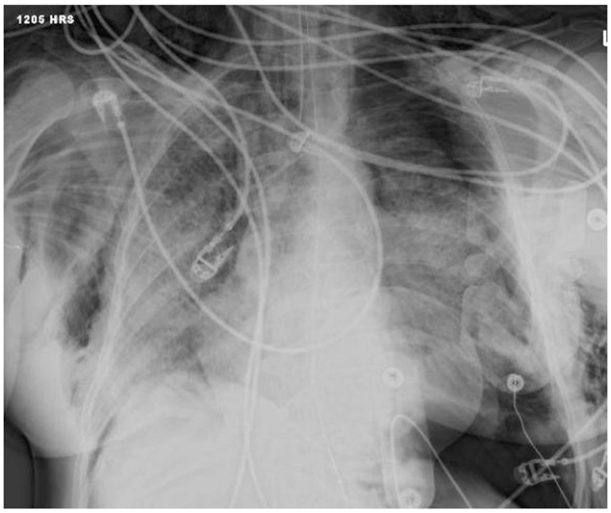

FIGURE 4. Deep sulcus sign revealing large left pneumothorax in a mechanically ventilated patient.

Because of the limitations of chest radiography, it is important to treat the patient and not the radiograph. When tension pneumothorax is suspected, if immediate bedside ultrasonography is not available, clinicians should proceed with immediate pleural evacuation to avoid further clinical decompensation.[46] If there is doubt in regards to the findings on a chest radiograph and the patient is stable, it is advised to seek the expert opinion of the radiologist or conduct further imaging with ultrasonography or chest CT scan.[47]

OCCULT PNEUMOTHORAX

With the increased use of CT scanning, the diagnosis of occult pneumothoraces has become more common. The occult pneumothorax is defined as a pneumothorax detected on a CT scan that was not clinically suspected or recognized on standard chest radiography.[48] The overall prevalence of trauma patients with an occult pneumothorax is 2% to 15% although this ranges widely and can be as high as 64% in multitrauma patients.[49] Given that, by definition, these patients present with a low initial clinical and radiographic suspicion of pneumothorax, management in regards to observation vs tube thoracostomy has been debated.[50] A recent multicenter study of occult pneumothoraces identified in mechanically ventilated critical care patients randomized patients to observation (unless drainage became clinically indicated) or immediate tube thoracostomy. Episodes of respiratory distress and difficulty in ventilation, and changes in radiographic imaging, were recorded and showed no significant difference between the two groups. There was also no significant difference in mortality (drainage, 22% and observation, 15%), hospital days, or median ICU time between the two groups. Thirty-one percent of the observed patients had subsequent tube thoracostomy placed nonurgently for worsening pneumothorax on imaging, and none of these patients had an increased morbidity. To date, this is the most inclusive trial examining occult pneumothoraces, and the encouraging result revealing no difference in morbidity should allow larger trials to definitively answer

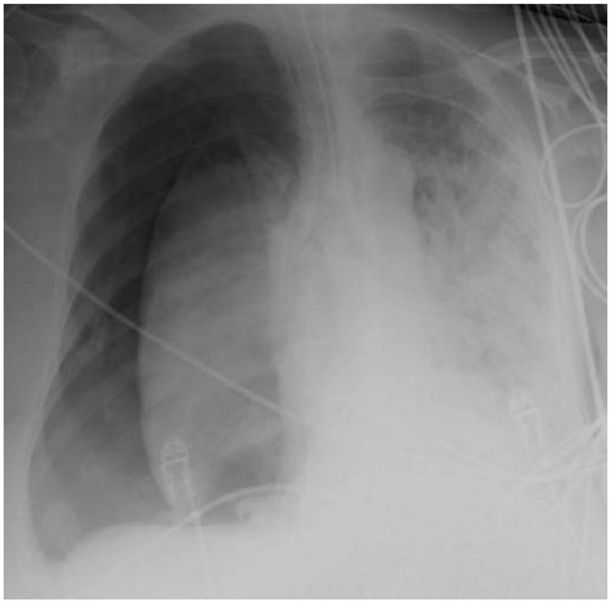

FIGURE 5. Spontaneous right pneumothorax in a ventilated ARDS patient.

the question regarding observation vs drainage. Until these trials are performed, the expert consensus suggests that clinical judgment be used to determine if drainage is indicated.[51]

Management of Pneumothorax

The cause of the pneumothorax, as well as the patient's underlying disease, greatly influence the treatment course and overall prognosis in critically ill patients.[37] The primary goal during the management of a pneumothorax is to evacuate air from the pleural space and allow apposition of the lung to the chest wall. Although many patients with a pneumothorax can be managed conservatively, the majority of patients in the ICU require pleural intervention.[52] The cause of pneumothoraces in critically ill patients has been shown to correlate with mortality risk. Pneumothorax secondary to barotrauma, progression to tension pneumothorax, and concurrent sepsis in a patient with a pneumothorax have been significantly and independently associated with an increased risk of death in the ICU.[44] The recent pleural management guidelines by the British Thoracic Society recommend intercostal drainage for all pneumothoraces in patients on a mechanical ventilator, as well as for those exhibiting signs or suspicion of tension physiology, traumatic pneumo- or hemothorax, or postsurgical pneumothoraces.[53] The role of manual aspiration in ventilated patients has not been studied, and there are currently no expert guidelines to suggest that manual aspiration has a role in the management of these patients.

Emergent Needle Decompression

Tension pneumothorax is a medical emergency that requires immediate intervention. As discussed earlier, if there is a high clinical suspicion of tension pneumothorax without the availability of bedside ultrasonography, definitive therapy should not be delayed while awaiting radiographic confirmation because the delay in care may result in further respiratory and hemodynamic decompensation.[41] Tension pneumothorax in the ventilated patient presents with the rapid development of hypoxemia, hypotension, tachycardia, elevation in airway pressures, and cardiac arrest and, as such, it is critical that emergent decompression be performed.[54] Tension should also be suspected in the unstable patient who has received CPR, as well as in patients who already have a chest tube placed for pneumothorax, because the tube may have become kinked or otherwise obstructed. A larger bore (14- to 16-gauge needle) should be inserted into the suspected side in the second anterior intercostal space in the midclavicular line. In a subset of patients, a standard needle may not be long enough to penetrate the pleura in the second intercostal space. In these patients, access may be obtained between the fourth and fifth intercostal space in the midaxillary line. After needle decompression, a tube thoracostomy should be placed for definitive managment.[55]

Tube Thoracostomy

The standard treatment of pneumothorax in the critically ill ventilated patient remains tube thoracostomy.[56] A wide variety of chest tube sizes exist, ranging from 6F to 40F. Traditionally, large-bore chest tubes were used for pneumothorax, but more recently, smaller-bore tubes using the modified Seldinger technique have become widely available and have become the most common method used for insertion of a chest drain. The recent British Thoracic Society guidelines recommend that small-bore catheters be used as first-line therapy for the management of pneumothorax. The risk of serious complications associated with small-bore catheters is small, with a frequency of injury of 0.2% and a malposition rate of 0.6%. The biggest risk is drain blockage, with a rate of 8.1%, and this is easily prevented with scheduled sterile flushing to maintain patency.[55] Another previous concern was that small-bore tubes would not be able to adequately handle the volume of large air leaks as predicted by Poseuilles law, although this has not been shown to be a factor in the majority of studies.[57] A retrospective review of 62 ventilated patients who underwent small-bore chest tube drainage as the primary management of pneumothorax found a 68.6% success rate, defined as no residual air seen in the

follow-up chest radiograph, with no major complications.[58] These results compare favorably with previous data showing a success rate of 55% with the same definition for success as in the previous study with large bore tubes and support the use of small bore catheters as first-line therapy in the ICU.[44]

Thoracic Surgery Referral

In patients with a persistent air leak or failure of the lung to expand, current guidelines suggest that an early thoracic surgical consultation be requested within 3 to 5 days.[41] The decision to undergo surgical intervention in the ventilated or critically ill patient is not always straightforward, and there are little data to guide management in these patients. Overall, surgical intervention is considered very effective and safe, with a low recurrence rate and morbidity; however, most studies do not include critically ill patients.[59,60] The most recent American College of Chest Physicians consensus statement recommends video-assisted thoracoscopic surgery over thoracotomy as the preferred surgical approach.[61]

Bronchoscopic Management of Prolonged Air Leaks

As discussed earlier, standard-of-care management for prolonged air leaks remains tube thoracostomy drainage and video-assisted thoracoscopic surgery. However, many critically ill patients are not optimal surgical candidates. Until recently, limited bronchoscopic interventions, such as the application of ethanol, fibrin, or acrylic glue, or the placement of metal coils, decalcified spongy calf bone, or Watanabe spigots, have been used with limited degrees of success.[62-65] Research efforts toward bronchoscopic lung volume reduction led to the invention of several one-way valves. These valves have also been used for the treatment of persistent air leaks.[66-68] The valve is an umbrella-shaped device that blocks distal airflow and facilitates local healing (Fig 6).

In a recent case series, eight valve placement procedures were performed in seven patients, and all patients had clinical improvement in the air leak without need for surgical intervention.[69] The device is placed with a flexible bronchoscope without the need for fluoroscopy and can easily be performed in an ICU setting after appropriate training. Although there are no available studies investigating ventilated or critically ill patients, valve placement procedures are currently indicated for the treatment of prolonged air leaks or leaks that are likely to be prolonged (defined as >7 days) following lobectomy, segmentectomy, or surgical lung-volume reduction. Additionally, the valves have been used successfully in an off-label fashion in patients with nonsurgically related prolonged air leaks due to lung cancer and SSP that failed conservative therapy.[70]

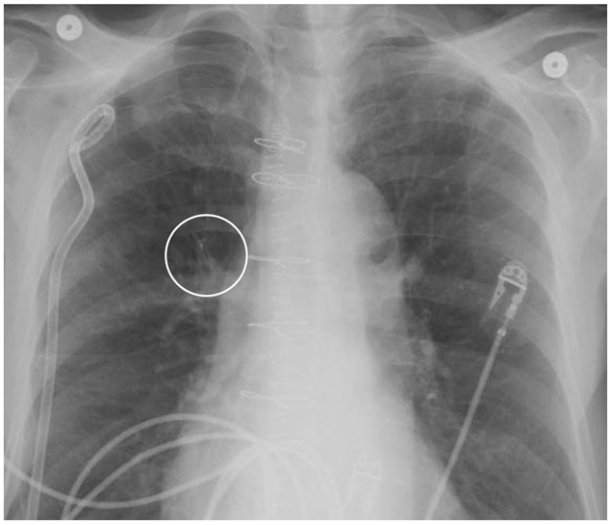

Figure 6. Chest radiograph showing placement of an endobronchial valve in the right upper lobe with resolution of pneumothorax prior to pigtail catheter removal.

Conclusions

Pneumothorax in the critically ill should be considered a medical emergency and requires a high index of suspicion, prompt recognition, and intervention (Table 1). Although CT scan remains the gold standard, the use of point-of-care ultrasonography by trained professionals has proven benefit in both the diagnosis and management of pneumothorax in the ICU. The majority of ventilated patients with a pneumothorax require immediate treatment with tube thoracostomy, given the high risk of progression to a tension pneumothorax. Those patients with a clinical suspicion of tension pneumothorax without the availability of bedside ultrasonography should be treated emergently with needle decompression followed by tube thoracostomy. Occult pneumothoraces in trauma patients may be observed without pursuing immediate procedural intervention if clinically appropriate.

Table 1— *Key Points: Diagnosis and Management of Pneumothorax in the Critically Ill*

Ultrasonography is more accurate than chest radiography for the diagnosis of pneumothorax in the ICU and affords the luxury of real-time information and repeated examinations.
It is acceptable to observe some patients with an occult pneumothorax if clinically appropriate.
In trained hands, an ultrasound examination may obviate the need for empiric tube thoracostomy for suspected tension pneumothorax.
Small-bore catheters are now preferred in the majority of ventilated patients.

Current expert guidelines recommend the use of small-bore catheters as first-line therapy for pleural intervention to treat a pneumothorax. Although critically ill patients are at higher risk, thoracic surgical consultation should be sought for prolonged air leaks, and if patients are not considered surgical candidates, alternative therapies may be considered.

Acknowledgments

Financial/nonfinancial disclosures: The authors have reported to *CHEST* that no potential conflicts of interest exist with any companies/organizations whose products or services may be discussed in this article.

References

1. Strange C. Pleural complications in the intensive care unit. *Clin Chest Med*. 1999;20(2):317-327.
2. de Latorre FJ, Tomasa A, Klamburg J, Leon C, Soler M, Rius J. Incidence of pneumothorax and pneumomediastinum in patients with aspiration pneumonia requiring ventilatory support. *Chest*. 1977;72(2):141-144.
3. Stocchetti N, Pagliarini G, Gennari M, et al. Trauma care in Italy: evidence of in-hospital preventable deaths. *J Trauma*. 1994; 36(3):401-405.
4. Noppen M, De Waele M, Li R, et al. Volume and cellular content of normal pleural fluid in humans examined by pleural lavage. *Am J Respir Crit Care Med*. 2000;162(3 pt 1): 1023-1026.
5. West JB. Why doesn't the elephant have a pleural space? *News Physiol Sci*. 2002;17:47-50.
6. Noppen M, De Keukeleire T. Pneumothorax. *Respiration*. 2008;76(2):121-127.
7. Noppen M, Alexander P, Driesen P, Slabbynck H, Verstraeten A. Manual aspiration versus chest tube drainage in first episodes of primary spontaneous pneumothorax: a multicenter, prospective, randomized pilot study. *Am J Respir Crit Care Med*. 2002; 165(9):1240-1244.
8. Noppen M, Dekeukeleire T, Hanon S, et al. Fluorescein-enhanced autofluorescence thoracoscopy in patients with primary spontaneous pneumothorax and normal subjects. *Am J Respir Crit Care Med*. 2006;174(1):26-30.
9. Bradley M, Williams C, Walshaw MJ. The value of routine expiratory chest films in the diagnosis of pneumothorax. *Arch Emerg Med*. 1991;8(2):115-116.
10. Haynes D, Baumann MH. Management of pneumothorax. *Semin Respir Crit Care Med*. 2010;31(6):769-780.
11. Tschopp JM, Rami-Porta R, Noppen M, Astoul P. Management of spontaneous pneumothorax: state of the art. *Eur Respir J*. 2006;28(3):637-650.
12. Baumann MH, Noppen M. Pneumothorax. *Respirology*. 2004; 9(2):157-164.
13. Papazian L, Forel JM, Gacouin A, et al; ACURASYS Study Investigators. Neuromuscular blockers in early acute respiratory distress syndrome. *N Engl J Med*. 2010;363(12):1107-1116.
14. Miller MP, Sagy M. Pressure characteristics of mechanical ventilation and incidence of pneumothorax before and after the implementation of protective lung strategies in the management of pediatric patients with severe ARDS. *Chest*. 2008;134(5):969-973.
15. Boussarsar M, Thierry G, Jaber S, Roudot-Thoraval F, Lemaire F, Brochard L. Relationship between ventilatory settings and barotrauma in the acute respiratory distress syndrome. *Intensive Care Med*. 2002;28(4):406-413.
16. Kopterides P, Siempos II, Armaganidis A. Prone positioning in hypoxemic respiratory failure: meta-analysis of randomized controlled trials. *J Crit Care*. 2009;24(1):89-100.
17. Briel M, Meade M, Mercat A, et al. Higher vs lower positive end-expiratory pressure in patients with acute lung injury and acute respiratory distress syndrome: systematic review and meta-analysis. *JAMA*. 2010;303(9):865-873.
18. Wilson H, Ellsmere J, Tallon J, Kirkpatrick A. Occult pneumothorax in the blunt trauma patient: tube thoracostomy or observation? *Injury*. 2009;40(9):928-931.
19. Rankine JJ, Thomas AN, Fluechter D. Diagnosis of pneumothorax in critically ill adults. *Postgrad Med J*. 2000;76(897): 399-404.
20. Ding W, Shen Y, Yang J, He X, Zhang M. Diagnosis of pneumothorax by radiography and ultrasonography: a meta-analysis. *Chest*. 2011;140(4):859-866.
21. Brook OR, Beck-Razi N, Abadi S, et al. Sonographic detection of pneumothorax by radiology residents as part of extended focused assessment with sonography for trauma. *J Ultrasound Med*. 2009;28(6):749-755.
22. Rantanen NW. Diseases of the thorax. *Vet Clin North Am Equine Pract*. 1986;2(1):49-66.
23. Mathis G. Thoraxsonography—Part I: chest wall and pleura. *Ultrasound Med Biol*. 1997;23(8):1131-1139.
24. Tsai TH, Yang PC. Ultrasound in the diagnosis and management of pleural disease. *Curr Opin Pulm Med*. 2003;9(4): 282-290.
25. Beckh S, Bölcskei PL, Lessnau KD. Real-time chest ultrasonography: a comprehensive review for the pulmonologist. *Chest*. 2002;122(5):1759-1773.
26. Lichtenstein D, Mezière G, Biderman P, Gepner A. The comet-tail artifact: an ultrasound sign ruling out pneumothorax. *Intensive Care Med*. 1999;25(4):383-388.
27. Maury E, Guglielminotti J, Alzieu M, Guidet B, Offenstadt G. Ultrasonic examination: an alternative to chest radiography after central venous catheter insertion? *Am J Respir Crit Care Med*. 2001;164(3):403-405.
28. Lichtenstein DA, Mezière G, Lascols N, et al. Ultrasound diagnosis of occult pneumothorax. *Crit Care Med*. 2005;33(6):1231-1238.
29. Soldati G, Testa A, Sher S, Pignataro G, La Sala M, Silveri NG. Occult traumatic pneumothorax: diagnostic accuracy of lung ultrasonography in the emergency department. *Chest*. 2008; 133(1):204-211.
30. Galbois A, Ait-Oufella H, Baudel JL, et al. Pleural ultrasound compared with chest radiographic detection of pneumothorax resolution after drainage. *Chest*. 2010;138(3):648-655.
31. Reissig A, Kroegel C. Accuracy of transthoracic sonography in excluding post-interventional pneumothorax and hydropneumothorax. Comparison to chest radiography. *Eur J Radiol*. 2005;53(3):463-470.
32. Vezzani A, Brusasco C, Palermo S, Launo C, Mergoni M, Corradi F. Ultrasound localization of central vein catheter and detection of postprocedural pneumothorax: an alternative to chest radiography. *Crit Care Med*. 2010;38(2):533-538.
33. Mayo PH, Goltz HR, Tafreshi M, Doelken P. Safety of ultrasound-guided thoracentesis in patients receiving mechanical ventilation. *Chest*. 2004;125(3):1059-1062.
34. Kelly AM, Weldon D, Tsang AY, Graham CA. Comparison between two methods for estimating pneumothorax size from chest X-rays. *Respir Med*. 2006;100(8):1356-1359.
35. Phillips GD, Trotman-Dickenson B, Hodson ME, Geddes DM. Role of CT in the management of pneumothorax in patients with complex cystic lung disease. *Chest*. 1997;112(1): 275-278.
36. Kelly AM, Loy J, Tsang AY, Graham CA. Estimating the rate of re-expansion of spontaneous pneumothorax by a formula

derived from computed tomography volumetry studies. *Emerg Med J*. 2006;23(10):780-782.
37. Rahman NM, Davies RJO, Gleeson FV. Pleural interventions: management of acute and chronic pneumothorax. *Semin Respir Crit Care Med*. 2008;29(4):427-440.
38. Tocino IM, Miller MH, Fairfax WR. Distribution of pneumothorax in the supine and semirecumbent critically ill adult. *AJR Am J Roentgenol*. 1985;144(5):901-905.
39. Rhea JT, vanSonnenberg E, McLoud TC. Basilar pneumothorax in the supine adult. *Radiology*. 1979;133(3 pt 1):593-595.
40. Schramel FM, Golding RP, Haakman CD, Sutedja TG, de Jong KA, Postmus PE. Expiratory chest radiographs do not improve visibility of small apical pneumothoraces by enhanced contrast. *Eur Respir J*. 1996;9(3):406-409.
41. MacDuff A, Arnold A, Harvey J; BTS Pleural Disease Guideline Group. Management of spontaneous pneumothorax: British Thoracic Society Pleural Disease Guideline 2010. *Thorax*. 2010;65(suppl 2):ii18-ii31.
42. Carr JJ, Reed JC, Choplin RH, Case LD. Pneumothorax detection: a problem in experimental design. *Radiology*. 1993;186(1):23-26.
43. Boland GW, Lee MJ, Sutcliffe NP, Mueller PR. Loculated pneumothoraces in patients with acute respiratory disease treated with mechanical ventilation: preliminary observations after image-guided drainage. *J Vasc Interv Radiol*. 1996; 7(2):247-252.
44. Chen KY, Jerng JS, Liao WY, et al. Pneumothorax in the ICU: patient outcomes and prognostic factors. *Chest*. 2002; 122(2):678-683.
45. Tagliabue M, Casella TC, Zincone GE, Fumagalli R, Salvini E. CT and chest radiography in the evaluation of adult respiratory distress syndrome. *Acta Radiol*. 1994;35(3): 230-234.
46. Gobien RP, Reines HD, Schabel SI. Localized tension pneumothorax: unrecognized form of barotrauma in adult respiratory distress syndrome. *Radiology*. 1982;142(1):15-19.
47. Mowery NT, Gunter OL, Collier BR, et al. Practice management guidelines for management of hemothorax and occult pneumothorax. *J Trauma*. 2011;70(2):510-518.
48. Wall SD, Federle MP, Jeffrey RB, Brett CM. CT diagnosis of unsuspected pneumothorax after blunt abdominal trauma. *AJR Am J Roentgenol*. 1983;141(5):919-921.
49. Guerrero-López F, Vázquez-Mata G, Alcázar-Romero PP, Fernández-Mondéjar E, Aguayo-Hoyos E, Linde-Valverde CM. Evaluation of the utility of computed tomography in the initial assessment of the critical care patient with chest trauma. *Crit Care Med*. 2000;28(5):1370-1375.
50. Moore FO, Goslar PW, Coimbra R, et al. Blunt traumatic occult pneumothorax: is observation safe? Results of a prospective, AAST multicenter study. *J Trauma*. 2011;70(5):1019-1025.
51. Ball CG, Kirkpatrick AW, Feliciano DV. The occult pneumothorax: what have we learned? *Can J Surg*. 2009;52(5): E173-E179.
52. Sahn SA, Heffner JE. Spontaneous pneumothorax. *N Engl J Med*. 2000;342(12):868-874.
53. Havelock T, Teoh R, Laws D, Gleeson F; BTS Pleural Disease Guideline Group. Pleural procedures and thoracic ultrasound: British Thoracic Society Pleural Disease Guideline 2010. *Thorax*. 2010;65(suppl 2):ii61-ii76.
54. Leigh-Smith S, Davies G. Indications for thoracic needle decompression. *J Trauma*. 2007;63(6):1403-1404.
55. Light RW. Tension pneumothorax. *Intensive Care Med*. 1994;20(7):468-469.
56. Gilbert TB, McGrath BJ, Soberman M. Chest tubes: indications, placement, management, and complications. *J Intensive Care Med*. 1993;8(2):73-86.
57. Liu CM, Hang LW, Chen WK, Hsia TC, Hsu WH. Pigtail tube drainage in the treatment of spontaneous pneumothorax. *Am J Emerg Med*. 2003;21(3):241-244.
58. Lin YC, Tu CY, Liang SJ, et al. Pigtail catheter for the management of pneumothorax in mechanically ventilated patients. *Am J Emerg Med*. 2010;28(4):466-471.
59. Hatz RA, Kaps MF, Meimarakis G, Loehe F, Müller C, Fürst H. Long-term results after video-assisted thoracoscopic surgery for first-time and recurrent spontaneous pneumothorax. *Ann Thorac Surg*. 2000;70(1):253-257.
60. Thomas P, Le Mee F, Le Hors H, et al. Results of surgical treatment of persistent or recurrent pneumothorax [in French]. *Ann Chir*. 1993;47(2):136-140.
61. Baumann MH, Strange C, Heffner JE, et al; AACP Pneumothorax Consensus Group. Management of spontaneous pneumothorax: an American College of Chest Physicians Delphi consensus statement. *Chest*. 2001;119(2):590-602.
62. Takaoka K, Inoue S, Ohira S. Central bronchopleural fistulas closed by bronchoscopic injection of absolute ethanol. *Chest*. 2002;122(1):374-378.
63. Watanabe S, Watanabe T, Urayama H. Endobronchial occlusion method of bronchopleural fistula with metallic coils and glue. *Thorac Cardiovasc Surg*. 2003;51(2):106-108.
64. Varoli F, Roviaro G, Grignani F, Vergani C, Maciocco M, Rebuffat C. Endoscopic treatment of bronchopleural fistulas. *Ann Thorac Surg*. 1998;65(3):807-809.
65. Watanabe Y, Matsuo K, Tamaoki A, et al. Bronchial occlusion with endobronchial Watanabe spigot. *J Bronchol*. 2003; 10(4):264-267.
66. Wood DE, McKenna RJ Jr, Yusen RD, et al. A multicenter trial of an intrabronchial valve for treatment of severe emphysema. *J Thorac Cardiovasc Surg*. 2007;133(1):65-73.
67. Ingenito EP, Wood DE, Utz JP. Bronchoscopic lung volume reduction in severe emphysema. *Proc Am Thorac Soc*. 2008;5(4):454-460.
68. Wood DE, Cerfolio RJ, Gonzalez X, Springmeyer SC. Bronchoscopic management of prolonged air leak. *Clin Chest Med*. 2010;31(1):127-133.
69. Gillespie CT, Sterman DH, Cerfolio RJ, et al. Endobronchial valve treatment for prolonged air leaks of the lung: a case series. *Ann Thorac Surg*. 2011;91(1):270-273.
70. Schiavon M, Marulli G, Zuin A, et al. Endobronchial valve for secondary pneumothorax in a severe emphysema patient. *Thorac Cardiovasc Surg*. 2011;59(8):509-510.